

# DETECTING ORAL CANCER

## A Guide for Healthcare Professionals

### INCIDENCE AND SURVIVAL

Oral cancer accounts for roughly three percent of all cancers diagnosed annually in the United States. Approximately 53,000 people will be diagnosed with oral cancer each year and about 10,800 will die from the disease. On average, 66 percent of those with the disease will survive more than 5 years.

### THE IMPORTANCE OF EARLY DETECTION

*It's important to find oral cancer early when it can be treated more successfully.*

The 5-year relative survival rate for those with localized disease at diagnosis is 85 percent compared with only 40 percent for those whose cancer has metastasized. Early detection of oral cancer is often possible. Tissue changes in the mouth that might signal the beginnings of cancer often can be seen and felt easily.

### WARNING SIGNS

#### Lesions that might signal oral cancer

Two lesions that could be precursors to cancer are leukoplakia (white lesions) and erythroplakia (red lesions). Although less common than leukoplakia, erythroplakia and lesions with erythroplakic components have a much greater potential for becoming cancerous. Any white or red lesion that does not resolve itself in 2 weeks should be reevaluated and considered for biopsy to obtain a definitive diagnosis.

#### Other possible signs/symptoms of oral cancer

Possible signs/symptoms of oral cancer that your patients may report: a lump or thickening in the oral soft tissues; a sore throat or a feeling that something is caught in the throat; difficulty chewing, swallowing, or speaking; ear pain; difficulty moving the jaw or tongue; hoarseness; numbness of the tongue or other areas of the mouth; or swelling of the jaw—in patients with dentures, swelling may produce a complaint that dentures have become ill-fitting or uncomfortable.

If the above problems persist for more than 2 weeks, a thorough clinical examination and laboratory tests, as necessary, should be performed to obtain a definitive diagnosis. If a diagnosis cannot be obtained, referral to the appropriate specialist is indicated.

### RISK FACTORS

#### Tobacco & Alcohol Use

Tobacco use (cigarettes, cigars, pipes, and smokeless tobacco) is a risk factor for oral cancer. Heavy alcohol use also increases the chances of developing the disease. The risk is even greater for people who use both tobacco and alcohol than for those who use only tobacco or only alcohol.

#### HPV

Infection with the sexually transmitted human papillomavirus (specifically the HPV 16 type) has been linked to a subset of oral cancers.

#### Age

Risk increases with age. Oral cancer most often occurs in people over the age of 40.

#### Sun exposure

Cancer of the lip can be caused by sun exposure.

### WHAT YOU CAN DO

A regular dental check-up is an excellent opportunity for a head and neck examination. Clinicians should be particularly vigilant in checking those who use tobacco or excessive amounts of alcohol.

- **EXAMINE** your patients using the head and neck examination described here
- **OBTAIN A HISTORY** of their alcohol and tobacco use
- **INFORM** your patients of the association between tobacco use, alcohol use, and oral cancer
- **TALK** to your patients about the HPV vaccine for themselves and their children (depending on their age)
- **FOLLOW-UP** to make sure a definitive diagnosis is obtained on any possible signs/symptoms

### THE EXAM

This exam is abstracted from the standardized oral examination method recommended by the World Health Organization. The method is consistent with those followed by the Centers for Disease Control and Prevention and the National Institutes of Health. It requires adequate lighting, a dental mouth mirror, two 2 x 2 gauze squares, and gloves; it should take no longer than 5 minutes.

## THE EXAMINATION

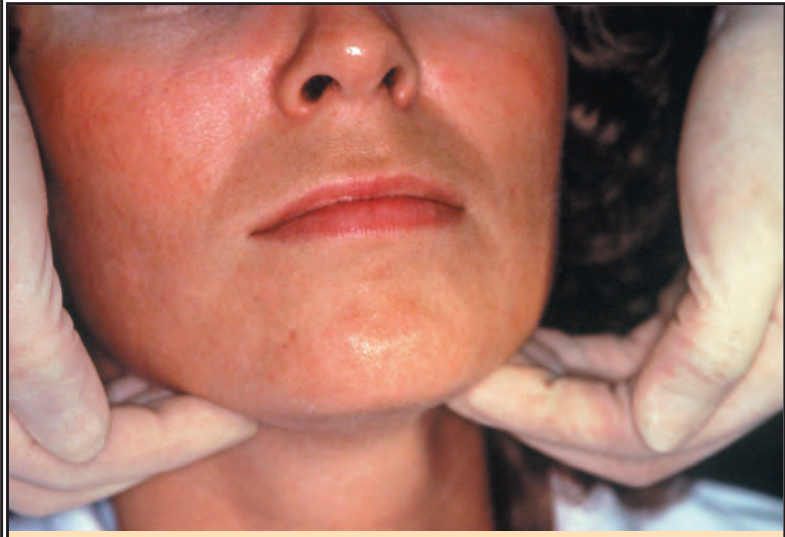

Figure 1—Face

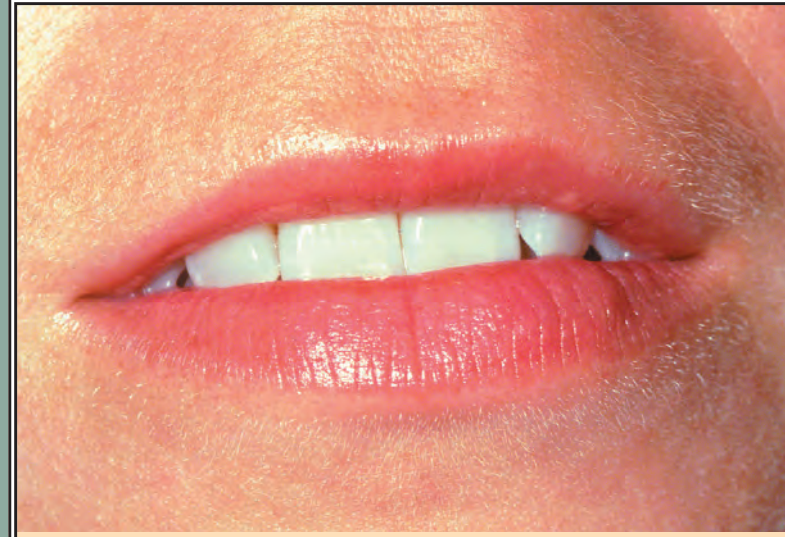

Figure 2—Lips

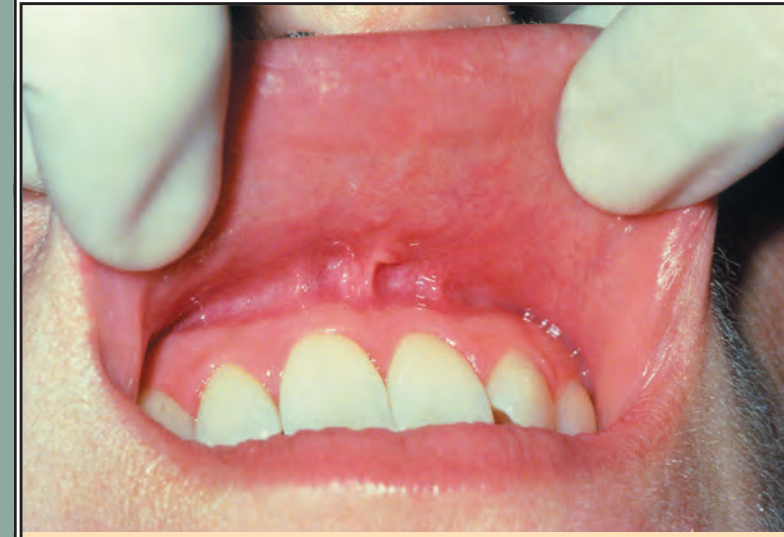

Figure 3—Labial mucosa

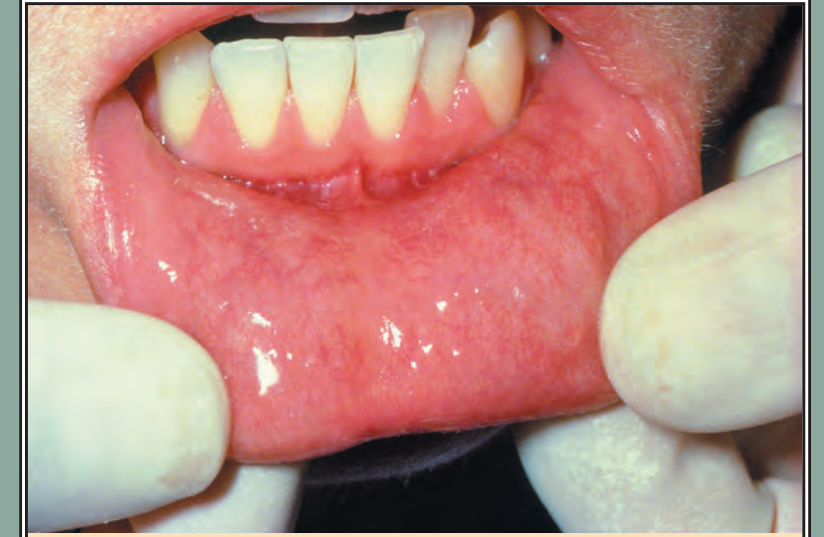

Figure 4—Labial mucosa

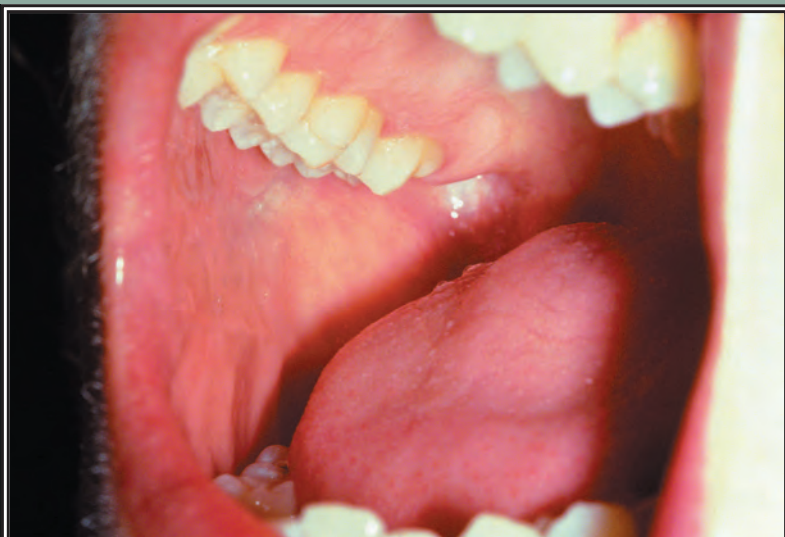

Figure 5—Right Buccal mucosa

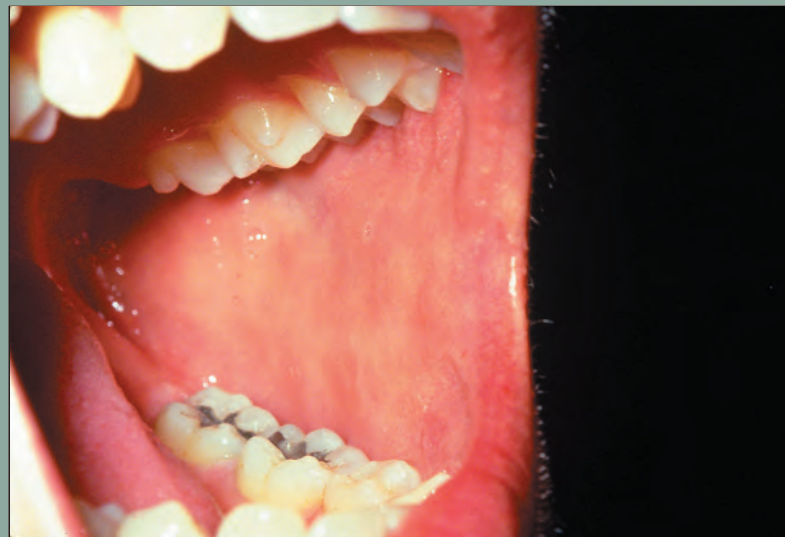

Figure 6—Left Buccal mucosa

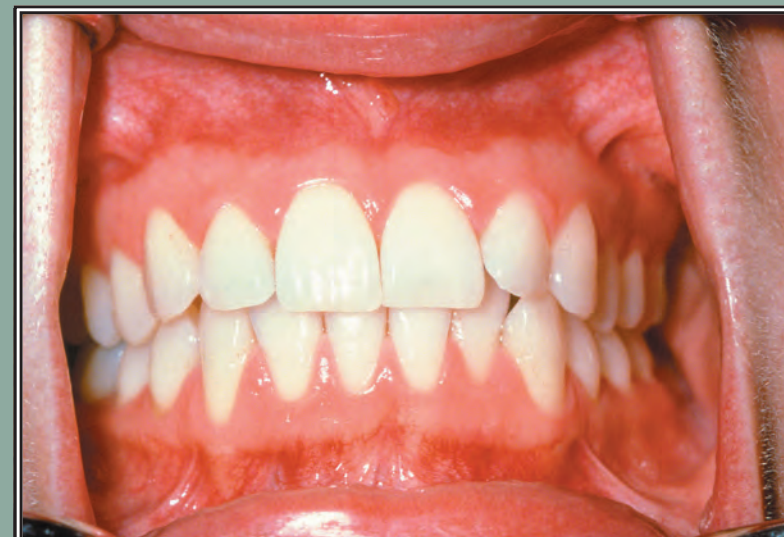

Figure 7—Gingiva

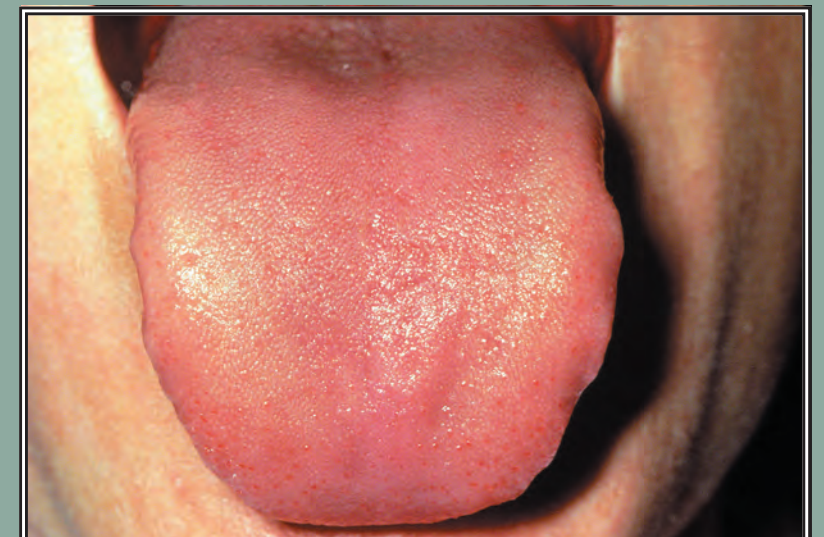

Figure 8—Tongue dorsum

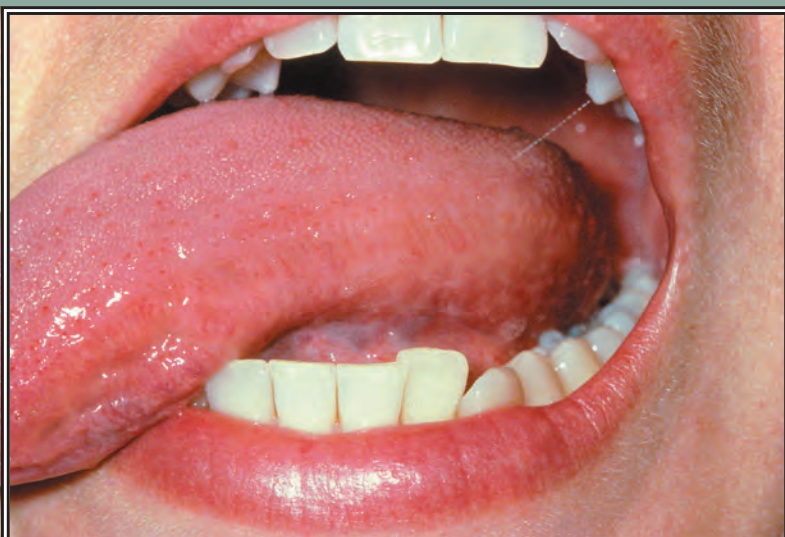

Figure 9—Tongue left margin

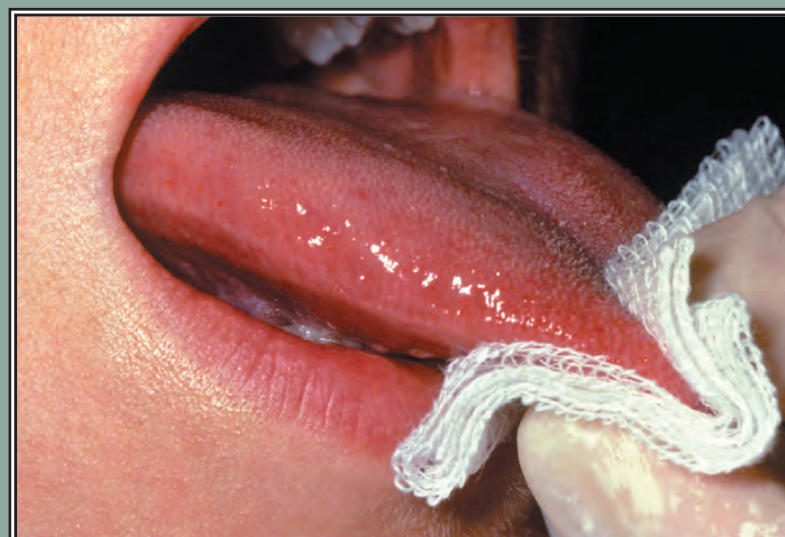

Figure 10—Tongue right margin

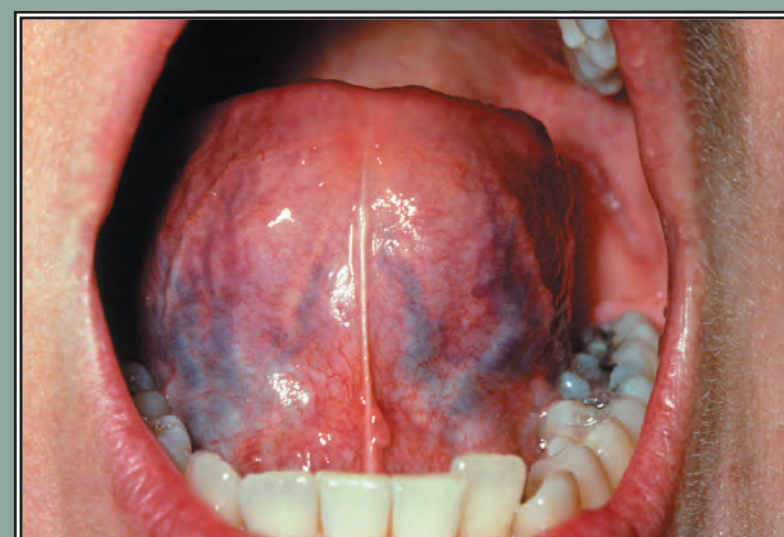


Figure 11—Tongue ventral

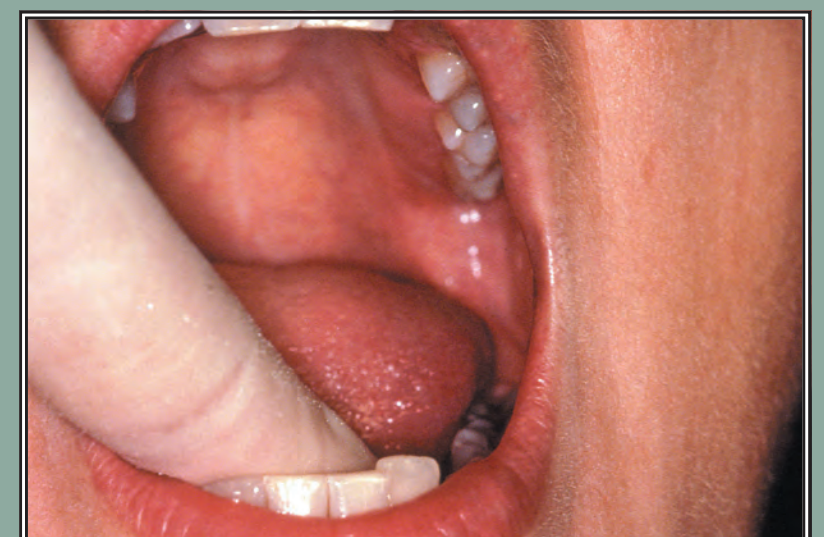

Figure 15—Palpation

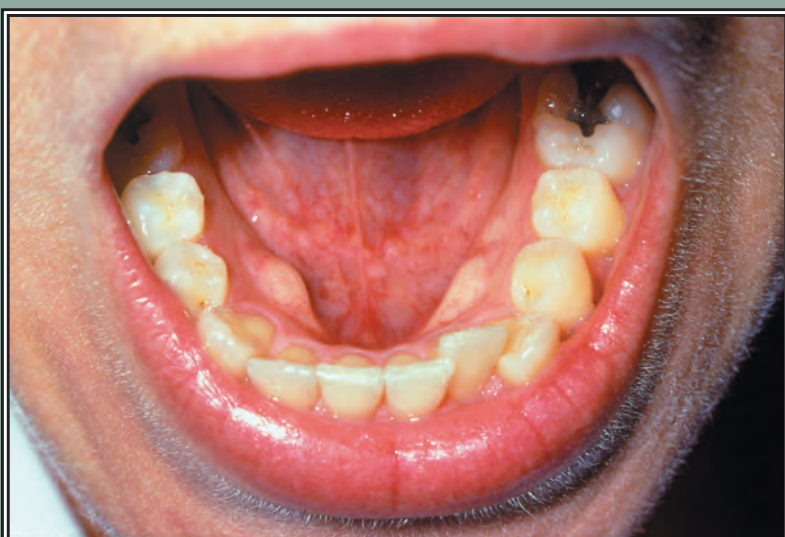

Figure 12—Floor of mouth

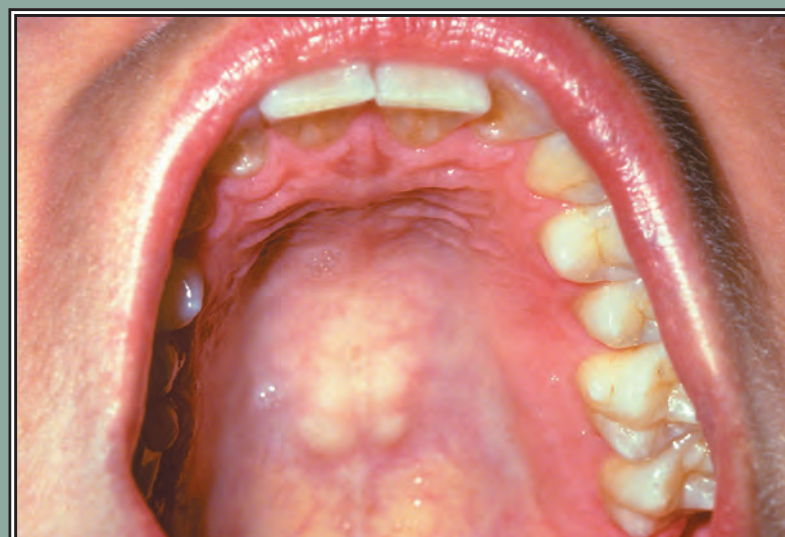


Figure 13—Hard palate

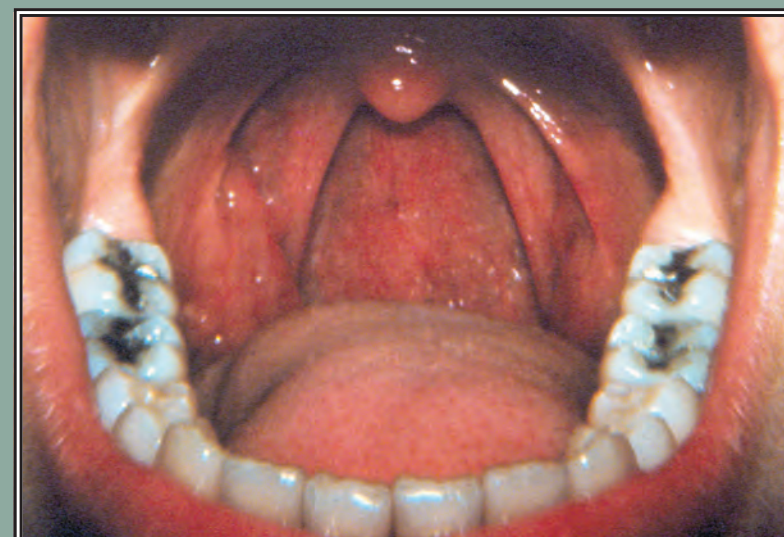


Figure 14—Oropharynx

The examination is conducted with the patient seated. Any intraoral prostheses are removed before starting. The extraoral and perioral tissues are examined first, followed by the intraoral tissues.

#### I. The Extraoral Examination

- ◆ FACE: (Figure 1)

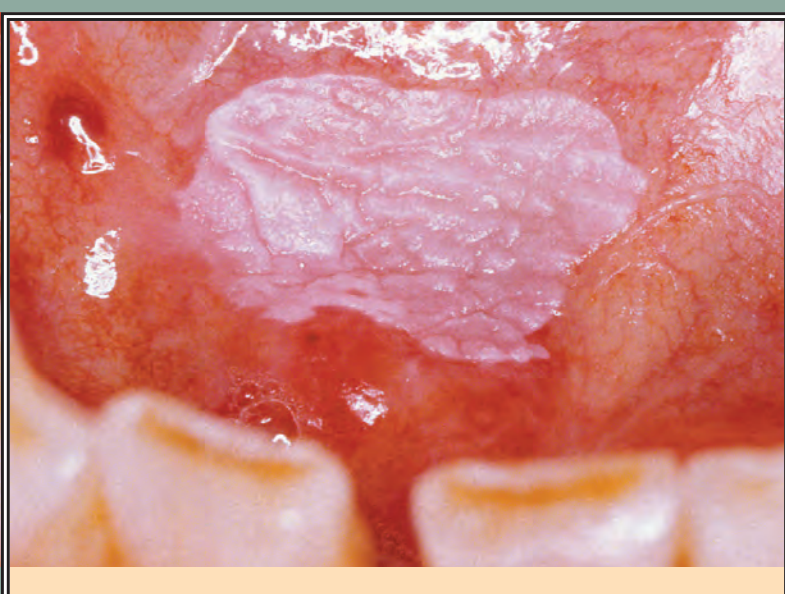
#### II. Perioral and Intraoral Soft Tissue Examination

- ◆ LIPS: (Figure 2)
- ◆ LABIAL MUCOSA: (Figures 3 and 4)
- ◆ BUCCAL MUCOSA: (Figures 5 and 6)
- ◆ GINGIVA: (Figure 7)

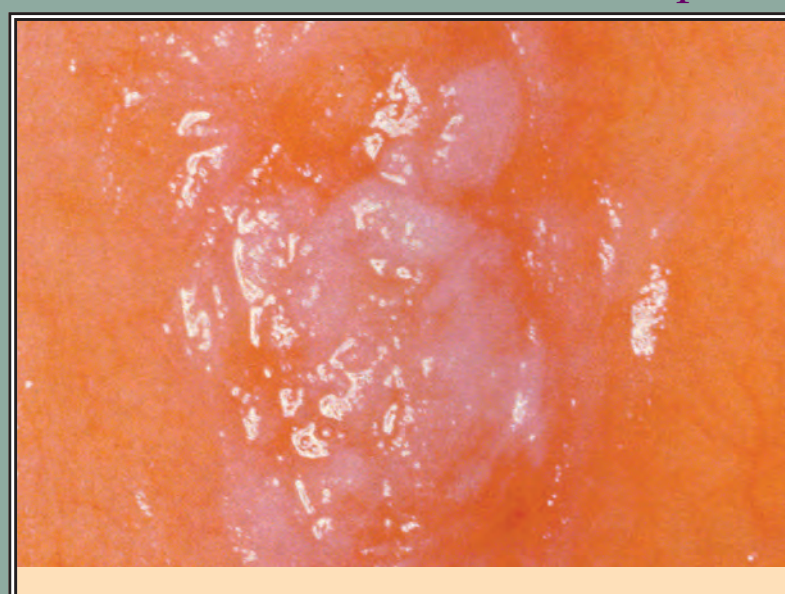- ◆ TONGUE: (Figures 8–11)
- ◆ FLOOR OF MOUTH: (Figure 12)
- ◆ PALATE: (Figures 13–15)

## ORAL LESIONS

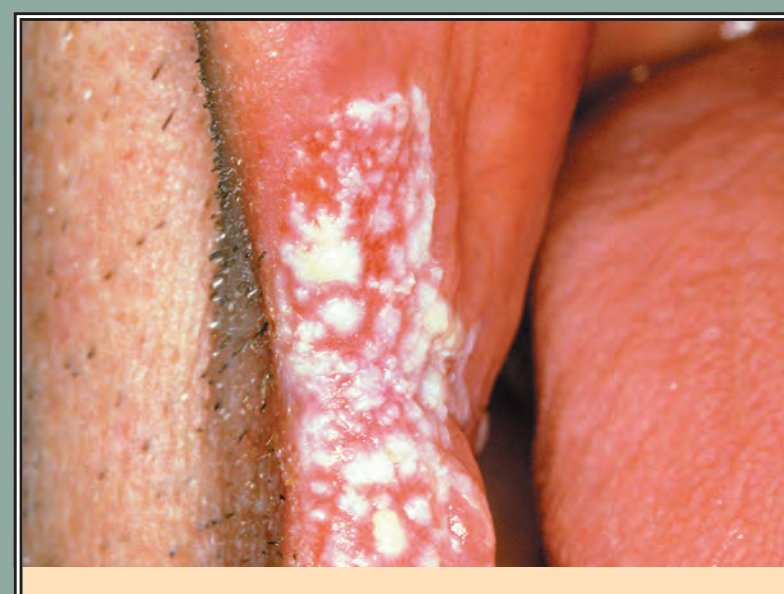### Suspicious for Oral Cancer



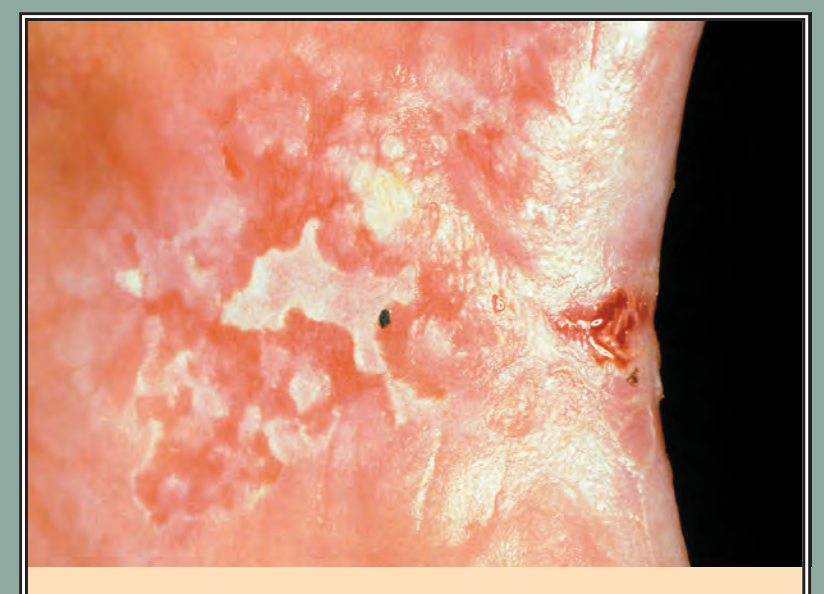Homogenous leukoplakia in the floor of the mouth in a smoker. Biopsy showed hyperkeratosis.



Clinically, a leukoplakia on left buccal mucosa. However, the biopsy showed early squamous cell carcinoma. The lesion is suspicious because of the presence of nodules.




Nodular leukoplakia in right commissure. Biopsy showed severe epithelial dysplasia.



Erythroleukoplakia in left commissure and buccal mucosa. Biopsy showed mild epithelial dysplasia and presence of candida infection. A 2-3 week course of anti-fungal treatment may turn this type of lesion into a homogenous leukoplakia.

**For more copies contact:**  
National Institute of Dental and Craniofacial Research  
National Oral Health Information Center  
1 NOHIC Way  
Bethesda, MD 20892-3500  
1-866-232-4528  
www.nidcr.nih.gov

This publication is not copyrighted.  
Make as many photocopies as you need.



August 2020

NIH...Turning Discovery Into Health®

# DETECTING

*A Guide for*

# ORAL

*Healthcare*

# CANCER

*Professionals*

U.S. DEPARTMENT OF HEALTH AND HUMAN SERVICES  
National Institutes of Health

## EXAM REVIEW

The examination is conducted with the patient seated. Any intraoral prostheses (dentures or partial dentures) are removed before starting the examination. The extraoral and perioral tissues are examined first, followed by the intraoral tissues.

### I. THE EXTRAORAL EXAMINATION

◆ **FACE:** (Figure 1) The extraoral assessment includes an inspection of the face, head, and neck. The face, ears, and neck are observed, noting any asymmetry or changes on the skin such as crusts, fissuring, growths, and/or color change. The regional lymph node areas are bilaterally palpated to detect any enlarged nodes, and if detected, their mobility and consistency. A recommended order of examination includes the preauricular, submandibular, anterior cervical, posterior auricular, and posterior cervical regions.

### II. PERIORAL AND INTRAORAL SOFT TISSUE EXAMINATION

The perioral and intraoral examination procedure follows a seven-step systematic assessment of the lips; labial mucosa and sulcus; commissures, buccal mucosa, and sulcus; gingiva and alveolar ridge; tongue; floor of the mouth; and hard and soft palate.

◆ **LIPS:** (Figure 2) Begin examination by observing the lips with the patient's mouth both closed and open. Note the color, texture and any surface abnormalities of the upper and lower vermilion borders.

◆ **LABIAL MUCOSA:** (Figures 3 and 4) With the patient's mouth partially open, visually examine the labial mucosa and sulcus of the maxillary vestibule and frenum and the mandibular vestibule. Observe the color, texture, and any swelling or other abnormalities of the vestibular mucosa and gingiva.

◆ **BUCCAL MUCOSA:** (Figures 5 and 6) Retract the buccal mucosa. Examine first the right then the left buccal mucosa extending from the labial commissure and back to the anterior tonsillar pillar. Note any change in pigmentation, color, texture, mobility and other abnormalities of the mucosa, making sure that the commissures are examined carefully and are not covered by the retractors during the retraction of the cheek.

◆ **GINGIVA:** (Figure 7) First, examine the buccal and labial aspects of the gingiva and alveolar ridges (processes) by starting with the right maxillary posterior gingiva and alveolar ridge and then move around the arch to the left posterior area. Drop to the left mandibular posterior gingiva and alveolar ridge and move around the arch to the right posterior area.

Second, examine the palatal and lingual aspects as had been done on the facial side, from right to left on the palatal (maxilla) and left to right on the lingual (mandible).

◆ **TONGUE:** (Figure 8) With the patient's tongue at rest, and mouth partially open, inspect the dorsum of the tongue for any swelling, ulceration, coating or variation in size, color, or texture. Also note any change in the pattern of the papillae covering the surface of the tongue and examine the tip of the tongue. The patient should then protrude the tongue, and the examiner should note any abnormality of mobility or positioning.

(Figure 9) With the aid of mouth mirrors, inspect the right and left lateral margins of the tongue.

(Figure 10) Grasping the tip of the tongue with a piece of gauze will assist full protrusion and will aid examination of the more posterior aspects of the tongue's lateral borders.

(Figure 11) Then examine the ventral surface. Palpate the tongue to detect growths.

◆ **FLOOR OF MOUTH:** (Figure 12) With the tongue still elevated, inspect the floor of the mouth for changes in color, texture, swellings, or other surface abnormalities.

◆ **PALATE:** (Figures 13 and 14) With the mouth wide open and the patient's head tilted back, gently depress the base of the tongue with a mouth mirror. First inspect the hard and then the soft palate.

(Figure 14) Examine all soft palate and oropharyngeal tissues.

(Figure 15) Bimanually palpate the floor of the mouth for any abnormalities. All mucosal or facial tissues that seem to be abnormal should be palpated.